



PATIENT

Teddy Fusari

SPECIES

Canine

BREED

Shih Tzu

SEX

Male Intact

AGE

14 years

WEIGHT

16.4lbs

PRESENTING CLINICAL SIGNS

History: Worsening chronic cough. Owner previously declined workup. Progressive heart murmur, now grade IV-V/V. BP: 150mmHg. Sent Rx for Hydrocodone, but difficult to fill due to supply issues (looking to compound).

ECHOCARDIOGRAM FINDINGS

2D, m-mode, color flow and Doppler imaging is available.

Left ventricle: LV is mildly dilated with hyperdynamic function.

Left atrium: The left atrium is severely dilated.

Mitral valve: Diffuse thickening of mitral valve leaflets with prolapse into the left atrial lumen. Severe eccentric mitral regurgitation, normal velocity.

Aortic valve/Aorta: The aortic valve is normal in morphology and mobility. Normal aortic outflow velocity; laminar flow. No aortic insufficiency.

Right ventricle: Mild RV dilation.

Right atrium: Mild RA dilation.

Tricuspid valve: The tricuspid valve appears mildly thickened with mild tricuspid regurgitation. TR velocity is mildly elevated consistent with early pulmonary hypertension.

Pulmonic valve/Pulmonary artery: The pulmonic valve is normal in morphology and mobility. Normal pulmonic outflow velocities. No pulmonic insufficiency.

Pericardium/other: No pericardial or pleural effusion noted. No obvious cardiac masses.

INTERPRETED BY

Maggie Machen
Lamy, DVM
DACVIM (Cardiology)

IMAGING PERFORMED BY

Pamela Harrigan,

HOSPITAL NAME

Littleton Animal
Hospital

REFERRING VET

Dr. Brooks

INVOICE

20765

DATE

8/26/21

2-Dimensional Measurements

Ao diam (cm)	1.3
LA diam (cm)	3.2
LA:Ao (Swe)	2.5
IVS thickness (cm)	0.64
LVID diastole (cm)	3.7
PW thickness (cm)	0.63
LVID systole (cm)	1.7
FS (%)	54

Doppler Measurements

PV Vmax (m/s)	0.65
AoV Vmax (m/s)	1.5
MR Vmax (m/s)	5.0
TR Vmax (m/s)	3.0
TR PG (mmHg)	37

INTERPRETATION OF THE FINDINGS

Chronic degenerative valve disease causing severe mitral and mild tricuspid regurgitation is identified. Severe left atrial enlargement indicates the risk for spontaneous congestive heart failure is elevated. Mild pulmonary hypertension is noted, which is likely secondary to chronic LA pressure elevation. No obvious additional issues such as systolic dysfunction is noted.

An increase in a chronic cough is noted in the history, which is suspected to be due to lower airway disease given the chronicity. That being said the patient is at high risk for decompensation and close monitoring of breathing at home is advised. Baseline chest radiographs are strongly recommended. Recommend institute cardiac supportive



PATIENT

Teddy Fusari

medications as below including a weak diuretic, Spironolactone. Cough suppression (up to q4-6 hours) is also recommended for mechanical/airway cough. Monitoring of sleeping breathing rates is recommended as the best way to screen for CHF at home.

SPECIES

Canine

Long term prognosis is guarded to poor; however, I am hopeful we can stabilize the patient for some time on medications. Once CHF develops, they are generally able to maintain a good quality of life for an average of 8-12 months. Patient will always be at risk for progression to CHF, development of arrhythmias/LA tear, syncope and/or sudden death in the future.

BREED

Shih Tzu

SEX

Male Intact

RECOMMENDATIONS

- Institute Pimobendan 0.3mg/kg PO 12h.
- Institute ACE-I (benazepril or enalapril) 0.5mg/kg PO q12h.
- Institute Spironolactone 1-2mg/kg PO q12h.
- Highly recommend baseline chest radiographs to screen for early decompensation.
- Continue hydrocodone with homatropine for QOL (0.2-0.4mg/kg PO up to q4-6 hours PRN for cough; available in 5/1.5mg tabs and 5mg/5ml liquid suspension).
- Elective anesthesia is not advised.
- Omega fatty acid supplementation and mild salt restriction may be of some long-term benefit.
- Monitor for development of a cough, labored breathing, exercise intolerance or collapse episodes. Monitoring of sleeping breathing rates is the best way to screen for progression to CHF at home.

AGE

14 years

WEIGHT

16.4lbs

INTERPRETED BY

Maggie Machen
 Lamy, DVM
 DACVIM (Cardiology)

PLAN

- A recheck renal panel and BP is recommended in 1-2 weeks, then every 3-4 months lifelong.
- A recheck echocardiogram is recommended in 4-6 months to screen for progression, sooner if clinical signs arise.

IMAGING PERFORMED BY

Pamela Harrigan,

HOSPITAL NAME

Littleton Animal
 Hospital

REFERRING VET

Dr. Brooks

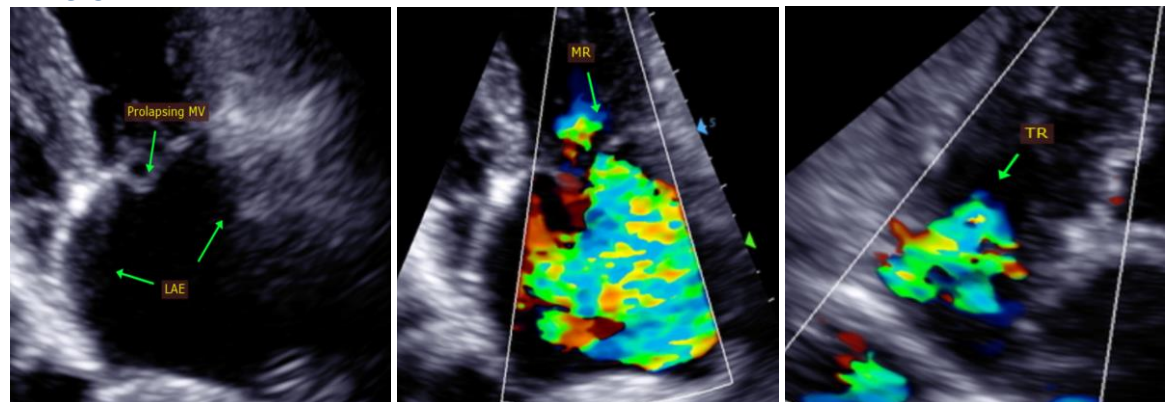
INVOICE

20765

DATE

8/26/21

IMAGES





PATIENT

Teddy Fusari

The information and recommendations provided are based on the images presented by the referring veterinarian. No evaluation can be communicated regarding pathology that was not visible in the image/video clips provided.

SPECIES

Canine

Thank you for this referral. This report was generated using transcription software, and minor dictation errors may be present. If the clinical or image interpretation does not parallel your findings or if I can be of any further assistance, please contact me.

BREED

Shih Tzu

Maggie Machen Lamy, DVM
Diplomate of the American College of Veterinary Internal Medicine (Cardiology)
info@sonopath.com

SEX

Male Intact

AGE

14 years

WEIGHT

16.4lbs

INTERPRETED BY

Maggie Machen
Lamy, DVM
DACVIM (Cardiology)

**IMAGING
PERFORMED BY**

Pamela Harrigan,

HOSPITAL NAME

Littleton Animal
Hospital

REFERRING VET

Dr. Brooks

INVOICE

20765

DATE

8/26/21